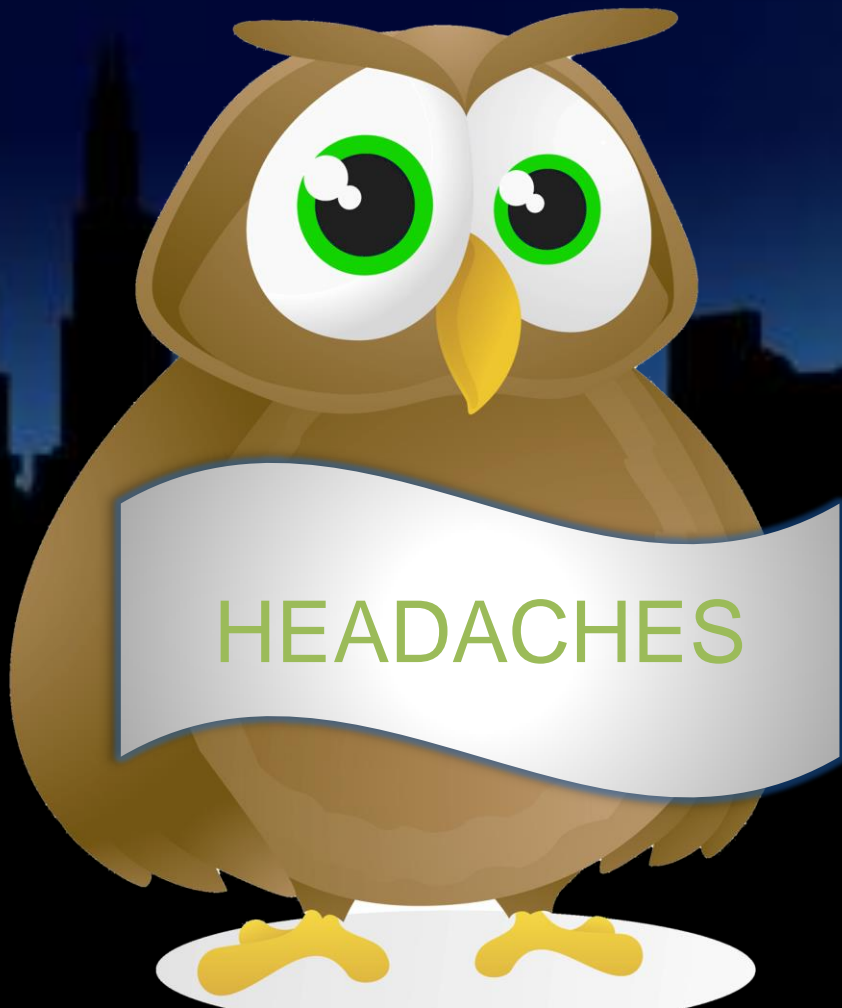

The McMaster *at night* Pediatric Curriculum



Blume, HK. "Pediatric Headache: a Review".
Pediatrics in Review 33 (12). 2012.

Objectives

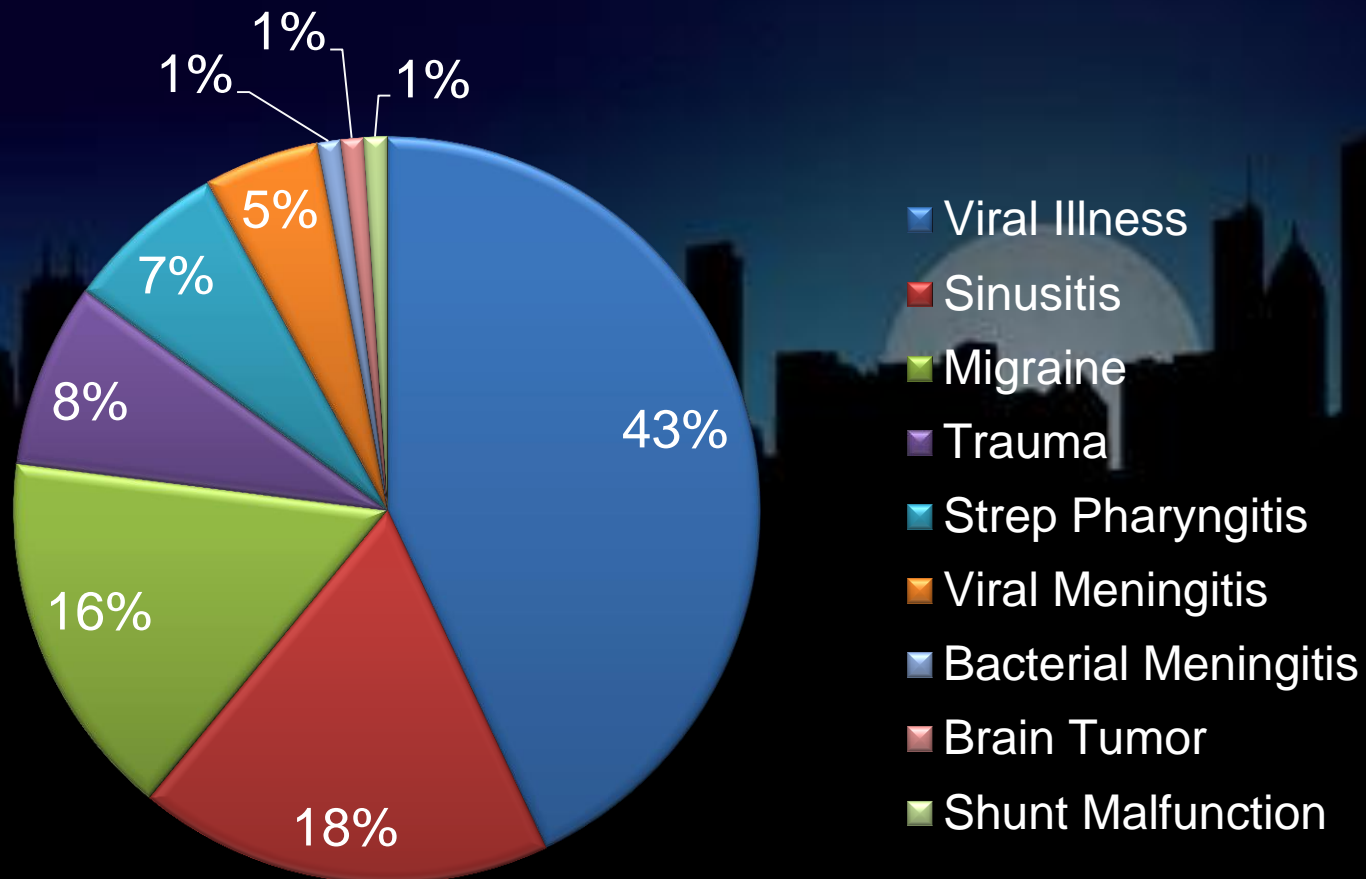
- Understand the **evaluation** of a child who has headache
- Learn the diagnostic criteria for pediatric **migraine**
- Recognize **red flags** for elevated ICP and other life-threatening etiologies
- Discuss **treatment** strategies for common headache types

Background

- Pediatric headaches are a common office and emergency department complaint
- The prevalence of headache increases with age: 27% of adolescent girls and 20% of adolescent boys describe frequent or severe headaches
- Most are **benign** etiologies but can nonetheless cause significant dysfunction
- Families are primarily interested in **ruling out serious illness** as well as **management strategies**

Background

Headaches in the Emergency Department



Test Your Knowledge

- Of the following 4 headache patterns, which is the most worrisome?
 - A. Acute single headache
 - B. Acute episodic headache
 - C. Chronic non-progressive headache
 - D. Chronic progressive headache

The Answer

- Acute episodic headaches and chronic non-progressive headaches are most commonly associated with the **primary** headache disorders such as migraine and tension headache
 - A single acute headache is usually primary, or a symptom of a viral infection (remember to rule out meningitis and SAH)
 - Chronic progressive headaches are most worrisome for **malignancy** and/or **ICP**, and imaging is indicated



The Case

- A 9-year-old girl has been referred to the emergency department follow-up clinic with a **6-month** history of **recurrent, bilateral, throbbing** headaches that occur about **once per week**, occasionally accompanied by **vomiting**
- She has no significant past medical history, and has been taking ibuprofen for the headaches which doesn't seem to help much
- Her mother is very anxious about a **brain tumor** and is requesting an MRI

History

What would you ask?

The background of the slide features a dark blue gradient. In the lower half, there is a black silhouette of a city skyline. A large, bright, circular full moon is positioned behind the skyline, partially obscured by the buildings. The overall mood is contemplative and historical.

History

- A **thorough history** is the single **most important** factor in the evaluation of headache
- Ask about onset, duration, timing, location, severity, character, progression, identified triggers
- **Alleviating** and **aggravating** factors (rest, movement, coughing, sneezing, bending over)
- **Associated** symptoms (fever, aura, nausea, vomiting, photophobia, phonophobia, focal deficits, confusion, ataxia, vision problems, sleep interruption, seizures)

History

- What **therapies** have been tried?
- A detailed **past medical history** includes medications, prior illnesses, head and neck surgeries, and allergies
- **Family history** of headaches, migraines, malignancy
- All patients merit a **social history** focusing on stressors, lifestyle, and the impact of headaches on function (adolescents require a full **HEADSSS** exam)
- A **review of systems** may reveal systemic disease

Physical Exam

What would you look for?

The background of the slide features a dark blue gradient. In the lower half, there is a black silhouette of a city skyline with various skyscrapers. A large, pale, circular moon is positioned behind the skyline, partially obscured by the buildings.

Physical Exam

- Ensure hemodynamic **stability** by measuring heart rate, **blood pressure**, respiratory pattern
- Temperature
- A **full neurological exam** includes mental status, visual acuity and fields, fundoscopy, cranial nerves, speech, power, deep tendon reflexes, sensation, gait and coordination
- Palpate the face and inspect the ears, nose and pharynx

Physical Exam

- Assess **neck** range of motion, Kernig's and Brudzinski's signs
- **Inspect the skin** for signs of systemic disease, toxidromes, neurocutaneous lesions, trauma, and self-harm
- Thyroid exam

Test Your Knowledge

- You have just finished assessing your 9-year-old girl the emergency department follow-up clinic with **chronic headaches**. Which of the following features would most prompt you to arrange urgent neuroimaging?
 - A. Vomiting, photophobia, worse with cough
 - B. Fever, neck stiffness, hypotension
 - C. Papilledema, fluctuating consciousness
 - D. Hypertension, blurry vision

The Answer

- Neuroimaging should be performed for children with **neurological findings** such as papilledema and altered consciousness, which indicate increased ICP
- Vomiting, photophobia, and worsening with movement are features of migraine
- Hypotension must be corrected before imaging (which is indicated prior to LP if there are focal deficits)
- Blurred vision and HTN could be ICP, but other etiologies are possible



Workup

What would you order?

The background of the slide features a dark blue gradient. In the lower half, there is a black silhouette of a city skyline. A large, bright white full moon is positioned behind the skyline, partially obscured by the buildings. The overall aesthetic is clean and professional.

Workup

- Investigations are guided by the history and physical (in many cases none are required)
- **Indications for neuroimaging:**
 - History that suggests neurologic deficits
 - Abnormal neurological exam and/or seizures
 - Recent onset of severe headache
 - Change in type of headache
 - Progressive headache severity or frequency
 - Headache waking patient from sleep
 - Underlying disease that predisposes to intra-cranial pathology (NF1, SCD)

Workup

- **MRI brain**
 - Structural abnormalities
 - Infections and abscesses
 - Inflammation
 - Ischemia
- **CT head**
 - Fractures
 - Acute hemorrhage
 - Rapid diagnosis of space-occupying lesion
- CT is more readily available and costs less, but involves radiation

Workup

- Full septic workup including **CSF analysis** if meningitis is suspected (LP is also indicated for IICP and sub-arachnoid hemorrhage)
- **TSH, T3, T4** if thyroid dysfunction suspected
- **BUN, Cr, and urinalysis** if hypertensive
- Serum and urine **drug screen, CO oximetry** as indicated by history and physical exam
- Consider **EEG** for seizures

Differential Diagnosis

Headaches	
Primary Headache Disorders	Vascular
Migraine	Subarachnoid hemorrhage
Tension-type headache	Cerebrovascular accident
Cluster headache	Malignant Hypertension
Infections	Sinus venous thrombosis
Viral respiratory infection	Vasculitis
Acute sinusitis	Malignancy
Otitis media	Primary brain tumor
Streptococcal pharyngitis	Brain metastases
Viral meningitis	Structural Lesions
Bacterial meningitis	Arteriovenous malformation
Brain abscess	Chiari malformation
Encephalitis	Shunt malfunction

Differential Diagnosis

Headaches	
Toxins/Medications	Systemic Disease
Medication overuse headache	Hypoglycemia
Rebound headache	Hypo & hyperthyroidism
Carbon monoxide	Sleep apnea
Caffeine	Epilepsy
Amphetamines	Mitochondrial disorders
Estrogen and oral contraceptives	Sickle cell disease
Steroids	Rheumatological disorders
Psychiatric Illness	Other
Depression	Trauma
Anxiety	Dental issues
Somatization	Idiopathic increased ICP

Pediatric Migraines

- Diagnostic criteria of migraine without aura
 - 5 or more attacks
 - Duration 1-72h
 - At least 2 of the following features:
 - Unilateral, bilateral or frontal
 - Pulsing quality
 - Moderate to severe intensity
 - Aggravated by physical activity
 - At least 1 of the following features:
 - Nausea or vomiting
 - Photophobia or phonophobia
 - Not attributed to another disorder

Pediatric Migraines

- Pediatric migraines are **common**, with a prevalence of 1-3% in children and 8-23% in adolescents
- Pediatric migraines are more likely to be **bilateral**, and most children do not have auras
- The pathophysiology of migraines is **incompletely understood** but represents a complex interaction between neurons and intracranial vasculature
- There is a strong **genetic component** but heritability does not follow a simple pattern

Pediatric Migraines

- **Migraine variants** are often referred for imaging due to clinical overlap with more serious pathology
- **Basilar**: aura of vertigo, ataxia, nystagmus, visual disturbance, dysarthria, tinnitus, or paraesthesias
- **Confusional**: aura of altered mental status and dysarthria
- **Hemiplegic**: prolonged hemiplegia, numbness, confusion, usually familial

Pediatric Migraines

- **Education** is the foundation of treatment
- **Lifestyle** changes include sleep hygiene, regular nutritious meals, adequate fluid intake, managing stressors and mood, and exercise
- Early, appropriate dosing of OTC analgesia is the mainstay of **abortive therapy**, and there is data to support the use of tryptans, primarily in adolescents
- Frequent disabling headaches may require **preventive therapy** with calcium channel blockers, beta blockers or anticonvulsants

Tension Headaches

- Tension headaches are more common than migraines but present less often because they are less disabling
- **Mild-moderate** pain lasting hours to days, described as “band-like” **pressure** or **tightening**
- Triggers are similar to migraine, especially **stressors** and mood disturbances
- **Reassurance**, **lifestyle** changes and **OTC analgesia** are the mainstays of therapy

Idiopathic Intracranial HTN

- Elevated ICP without a specific cause, also called **pseudotumor cerebri**
- The typical patient is an obese adolescent female
- Presents with daily headache, associated with nausea, vomiting, visual deficits, irritability or somnolence, and ataxia, but **no localizing signs**
- **Papilledema** is present on exam, CSF **opening pressure** is high (with subsequent normal analysis), and ventricles appear small on imaging

Idiopathic Intracranial HTN

- Treatment consists of **discontinuing exacerbating medications** (OCP, steroids, tetracyclines, lithium, isotretinoin), **weight control**, and treatment of systemic illness that may be contributing
- Most patients respond to **acetazolamide**, and furosemide is an alternative option
- Morbidity relates to post-papilledemal optic nerve atrophy, so frequent **ophthalmological follow-up** is required

Brain Tumors

- Brain tumors cause symptoms through **local mass effect**, **increased ICP**, and disruption of **metabolism**
- **Historical red flags** include progressive headaches, nighttime awakening, worse with valsalva, seizures, intractable vomiting, altered consciousness, and irreversible neurological deficits
- **Exam red flags** include papilledema, impaired mental status, focal deficits, and changes in vitals
- Review of symptoms may help localize the lesion (polyuria, polydipsia, ataxia, aphasia, etc.)

Subarachnoid Hemorrhage

- **Very rare** cause of headache in children, usually in the context of trauma
- Classic presentation is a severe, “**thunderclap**” headache
- Usually accompanied by changes in vitals and neurological deficits at the time of presentation
- Conditions such as sickle cell disease, AVMs, and coagulopathies may predispose, but still rare
- Suspicion merits urgent **neuroimaging**

Medications & Toxins

- **Medication overuse headache:** chronic daily headache resulting from analgesia > 15 days/month for > 3 months
- **Rebound headache:** acute headache resulting from discontinuation of analgesia
- Opioids and barbiturates are likely to worsen headache and should not be used for treatment
- Amphetamines, alcohol, caffeine, steroids and OCP are all associated with headache

Test Your Knowledge

- A 6-year-old boy from a refugee family living in East Hamilton for 1 year presents with 3 days of headache accompanied by worsening lethargy and confusion. On family history you note that both parents and all 5 siblings have had similar headaches recently. He is afebrile and tachycardic. What test is most likely to give the diagnosis?
 - A. MRI of the brain
 - B. CO-oximetry
 - C. Thick and thin peripheral blood smears
 - D. No tests are required for migraine variants

The Answer

- Carbon monoxide binds to hemoglobin with high affinity, producing carboxyhemoglobin
- The initial presentation is often headache, but can progress quickly to **behavioral changes, lethargy, confusion, ataxia, coma and death**



- Causes include furnaces, car exhaust and fires, and should be suspected when cohabitants share symptoms
- Treatment is supportive with **100% O₂** and possible hyperbaric therapy

Summary

- Although most pediatric headaches are **benign**, clinicians must be able to recognize disorders that cause secondary headaches
- A comprehensive **history** is the most important diagnostic tool followed by complete physical exam
- Further testing including imaging is **not routine** and is directed by history and exam
- Patients require a **multifaceted treatment plan** including education, lifestyle modification and analgesia



Fin